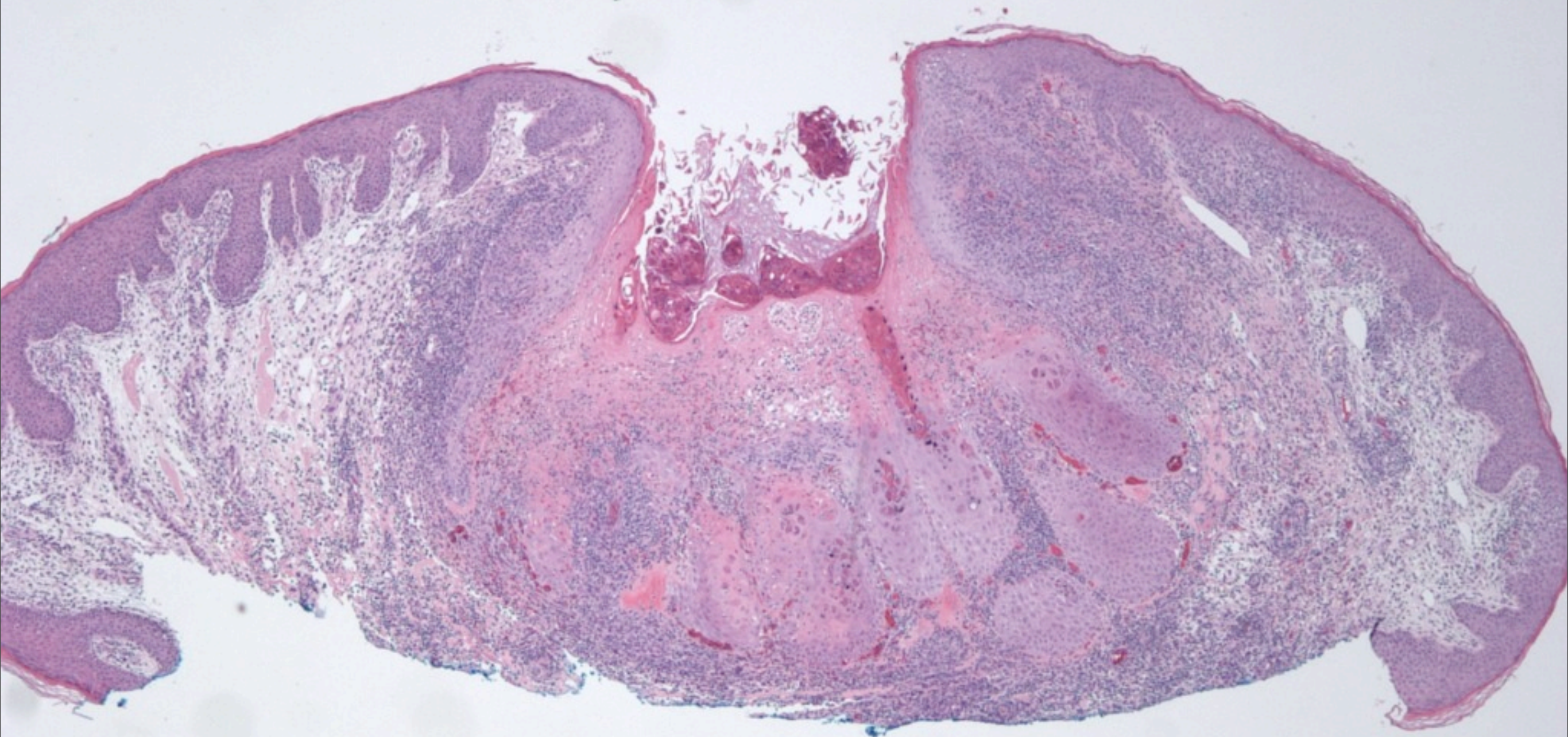
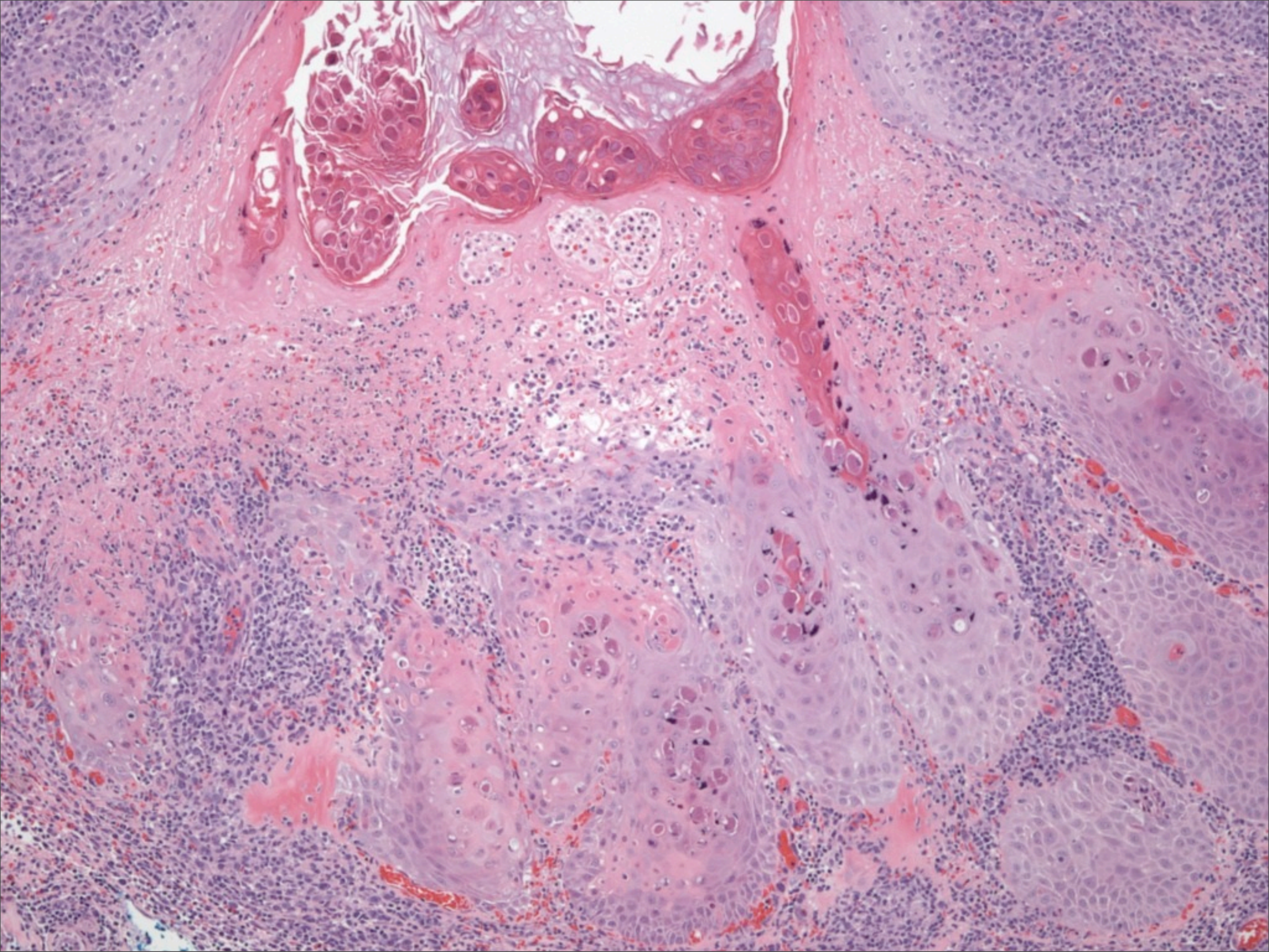


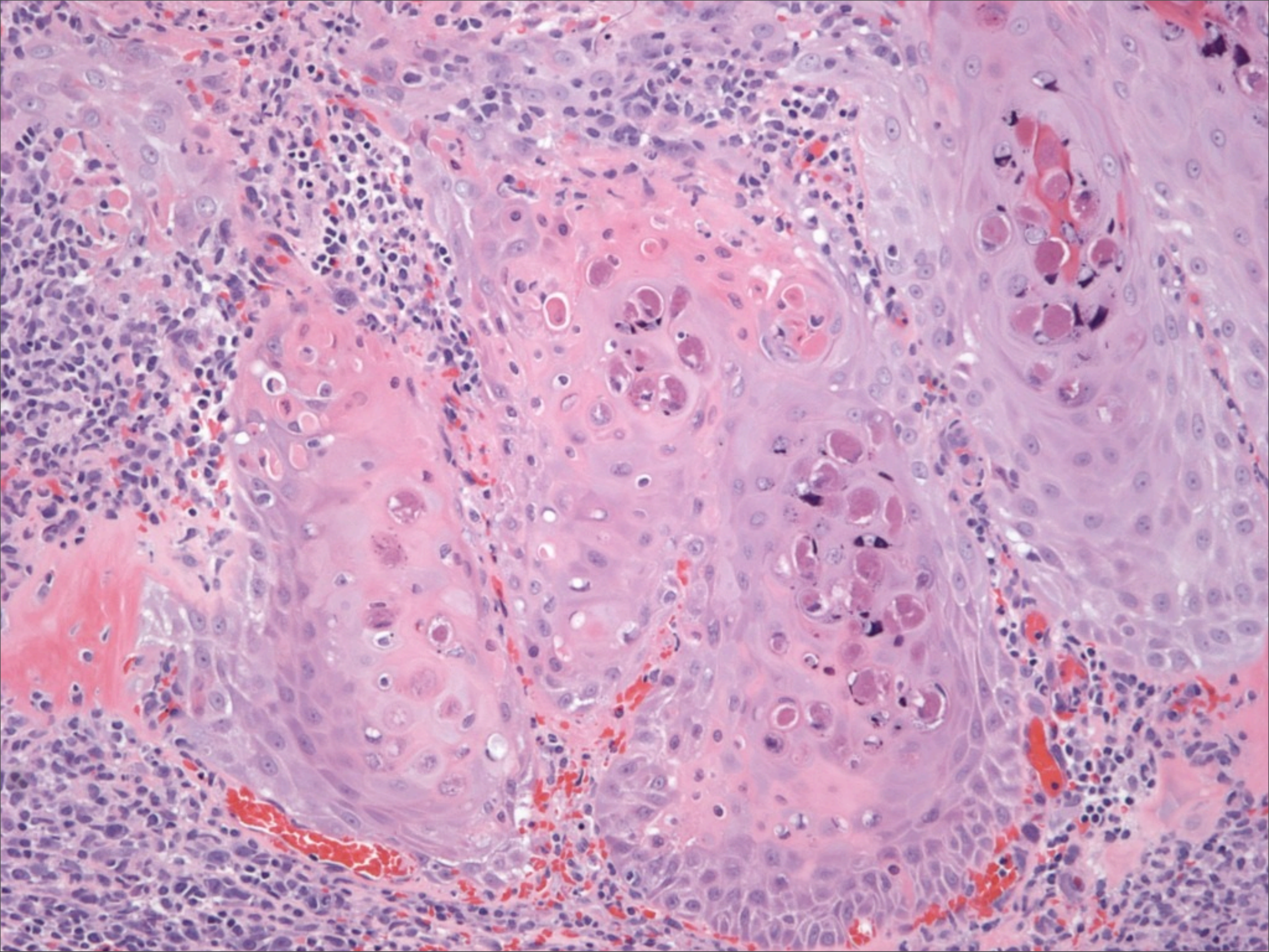
Dermatopathology

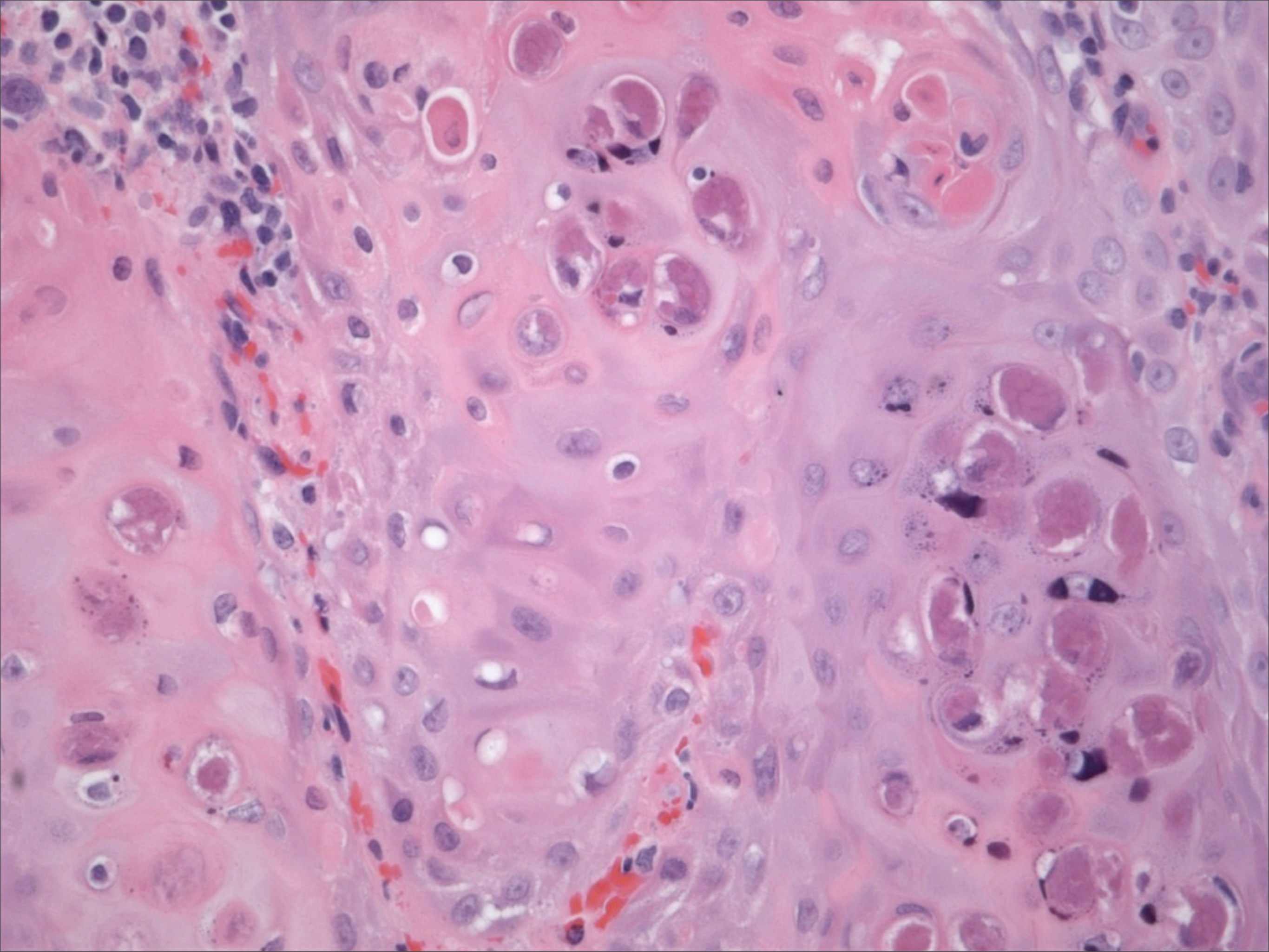
Slide Review Part 156

Paul K. Shitabata, M.D.
Dermatopathology Institute
Torrance, CA



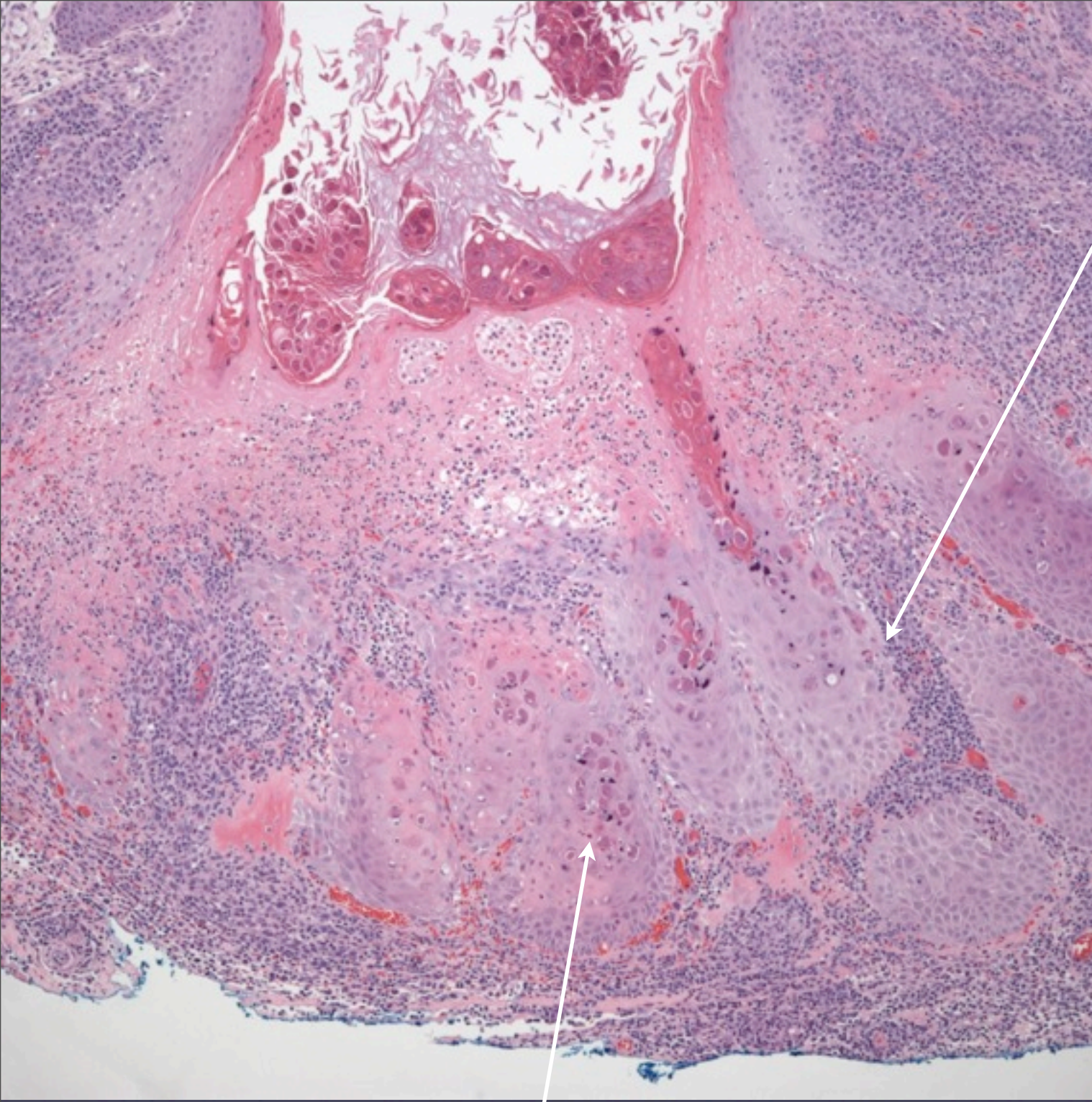




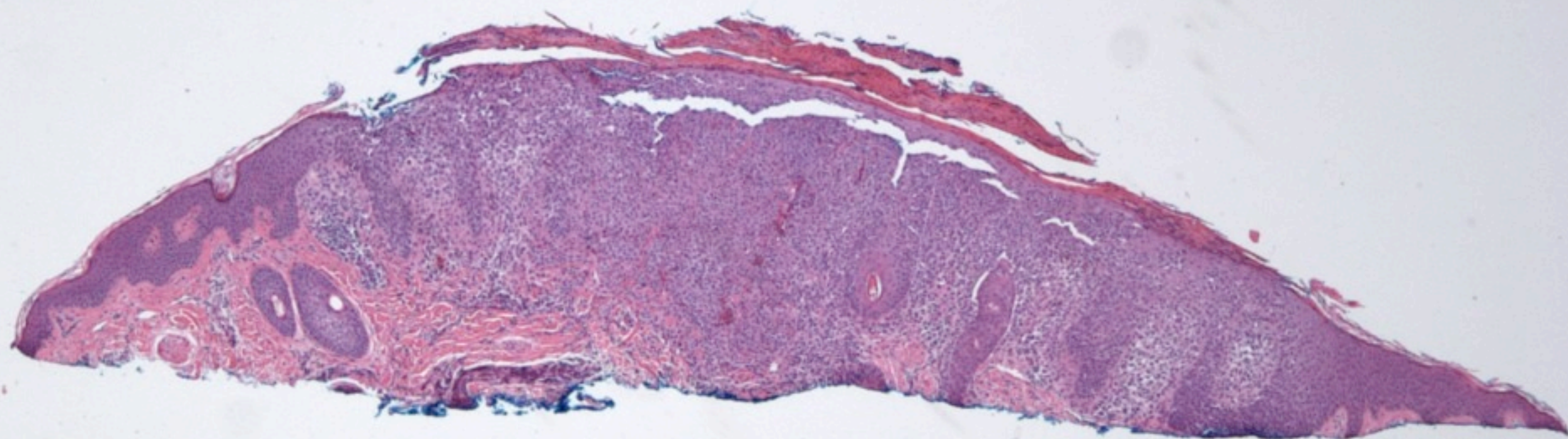


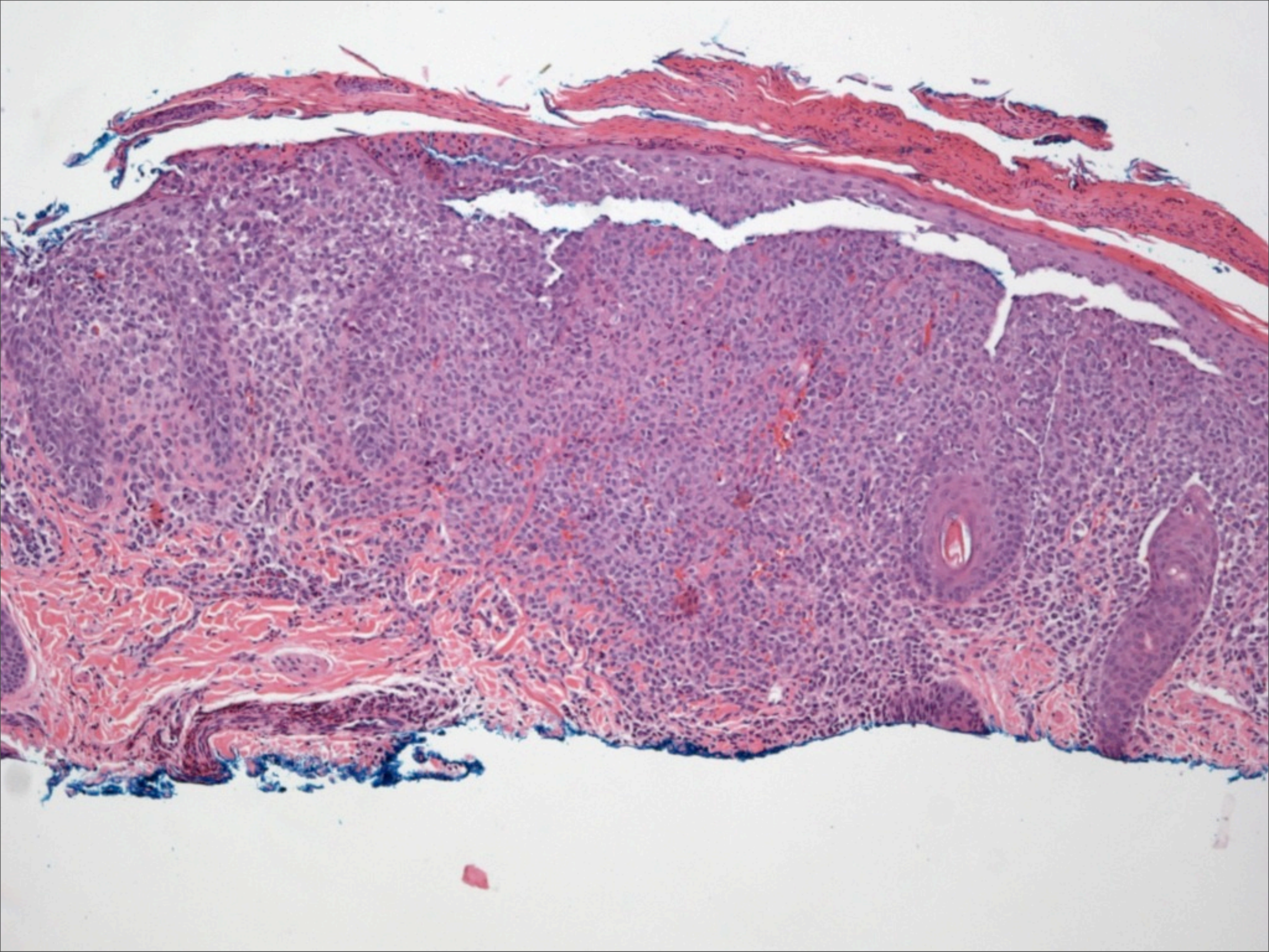
Molluscum Contagiosum, Inflamed

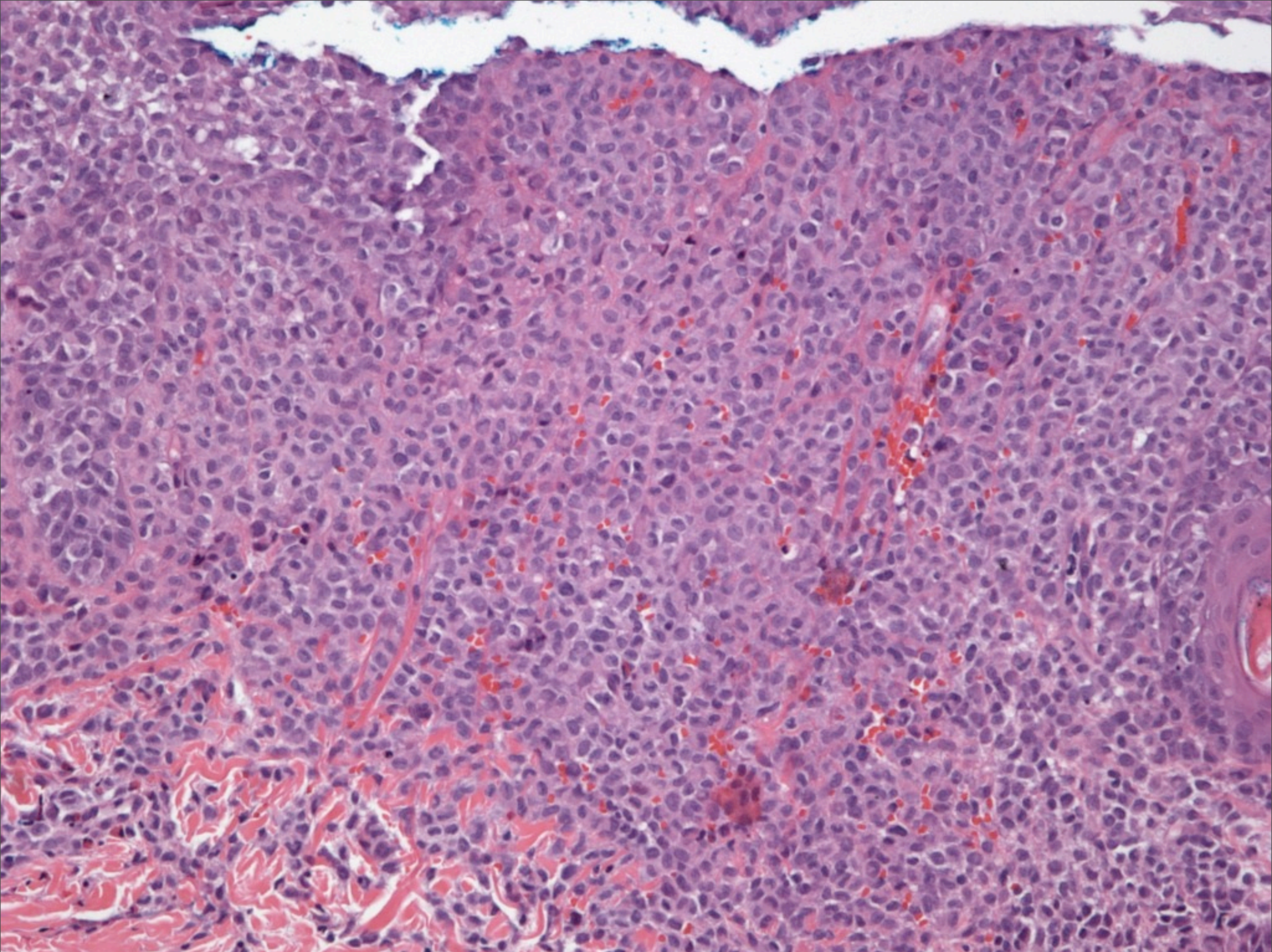
Inflammation may
obscure viral changes

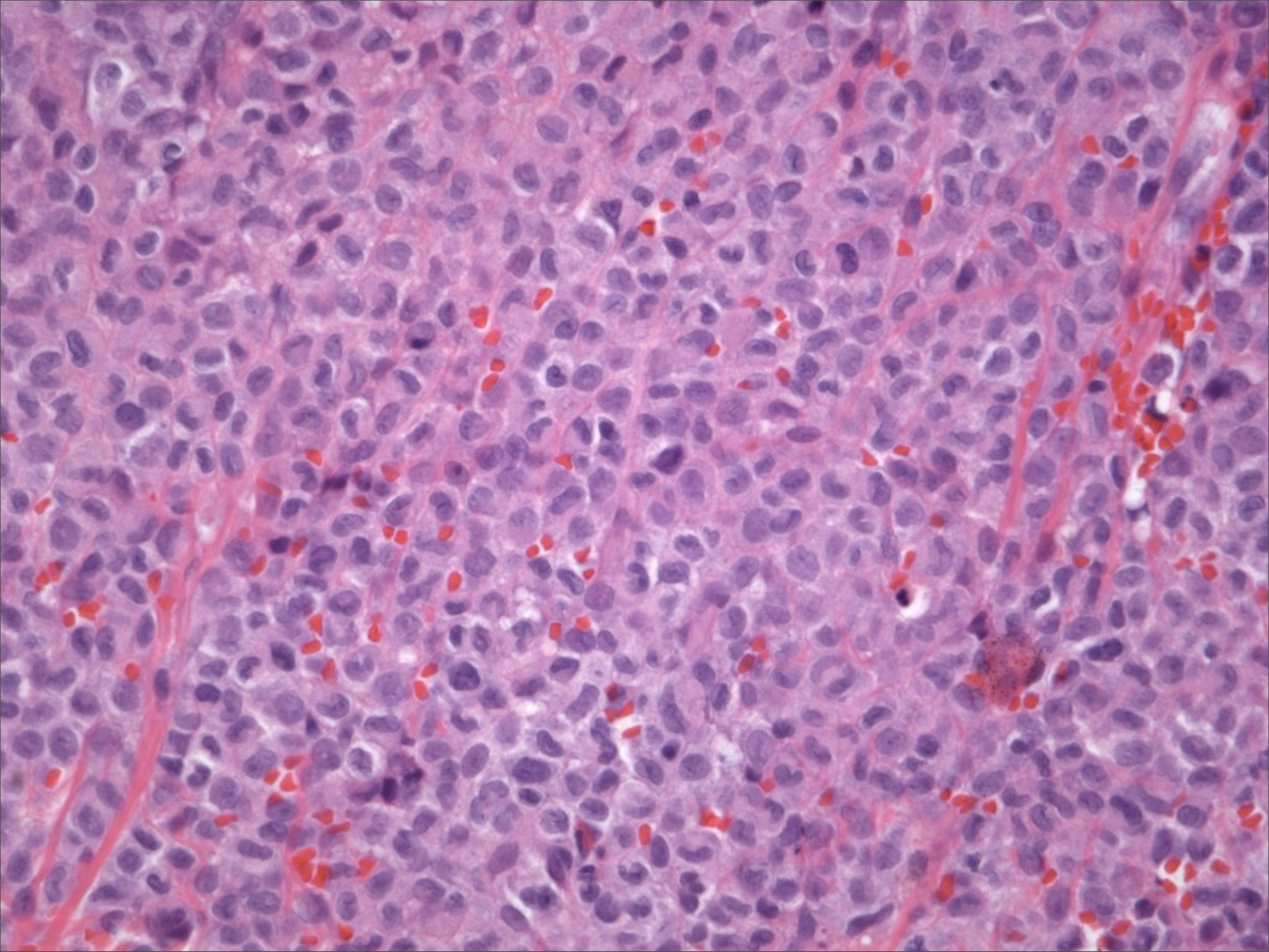


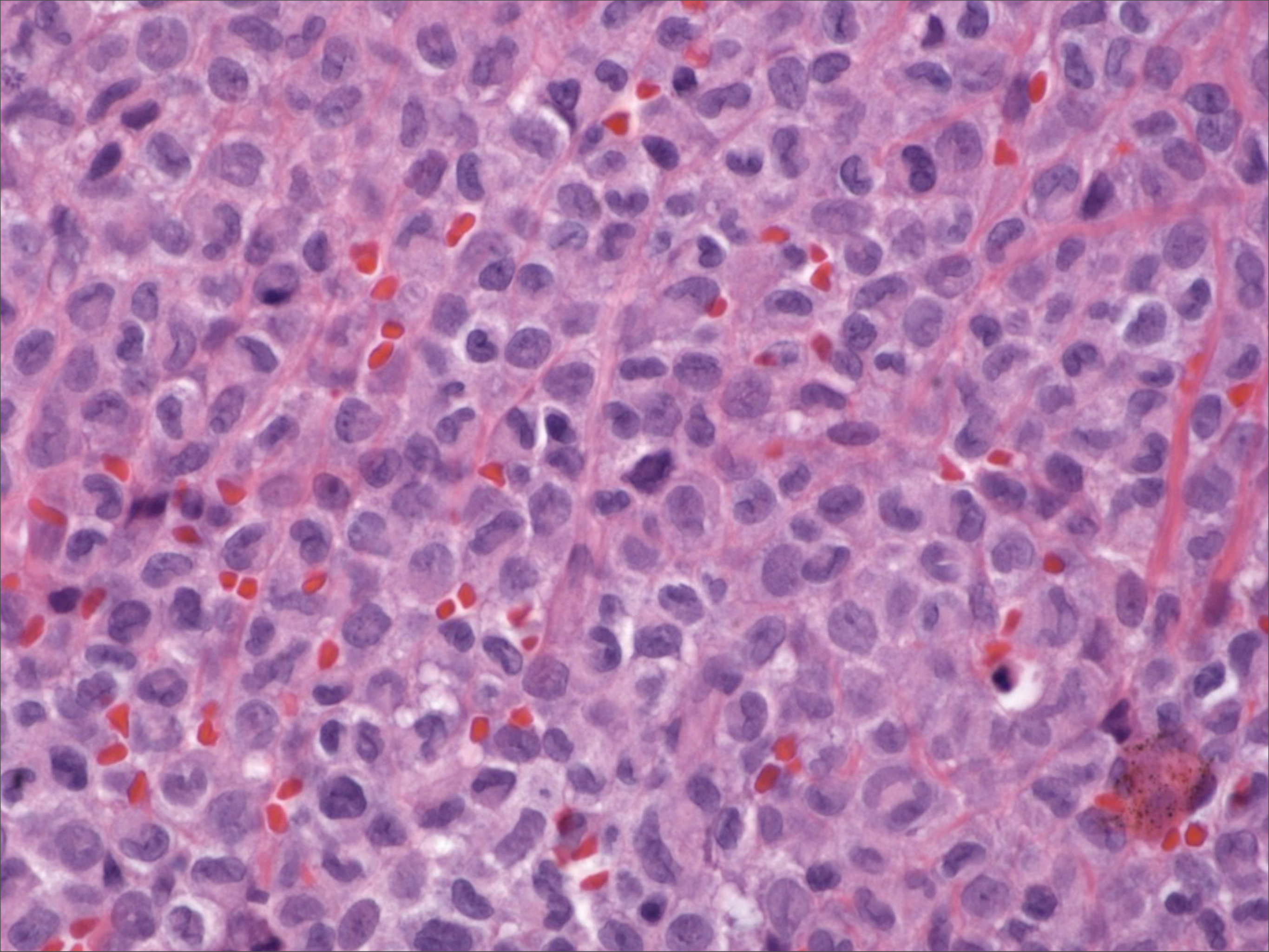
Viral cytopathic changes of
Molluscum bodies

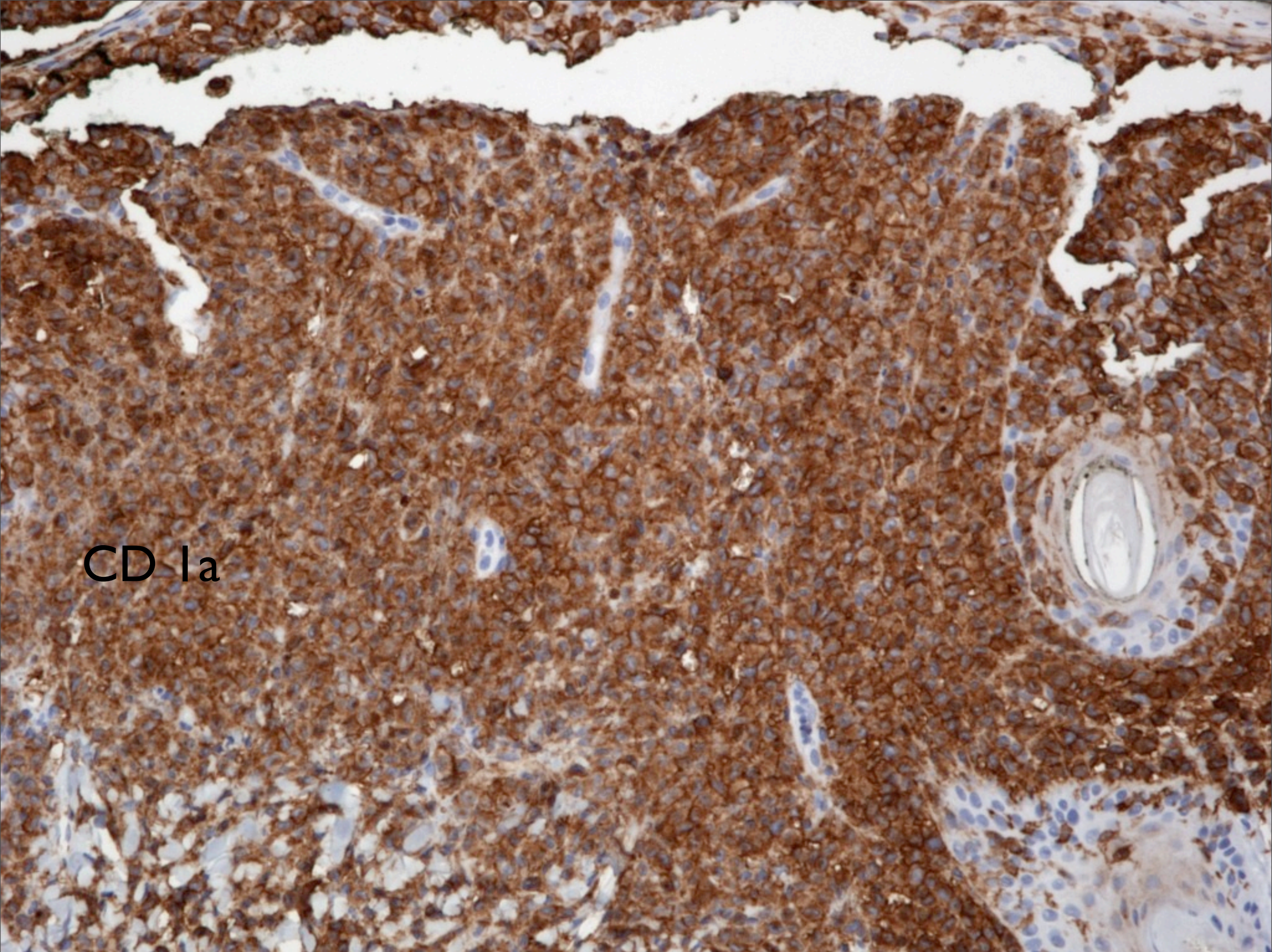






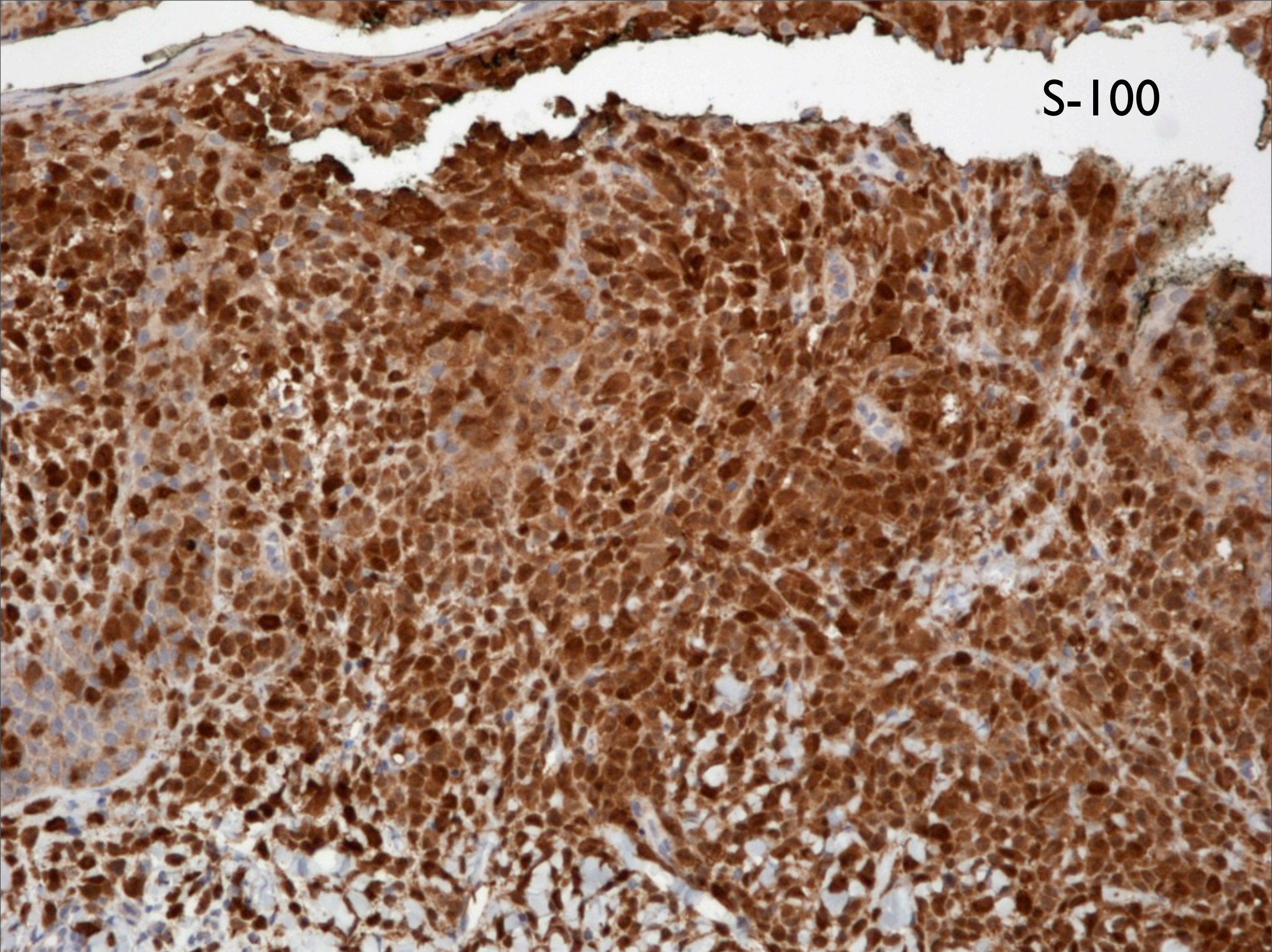




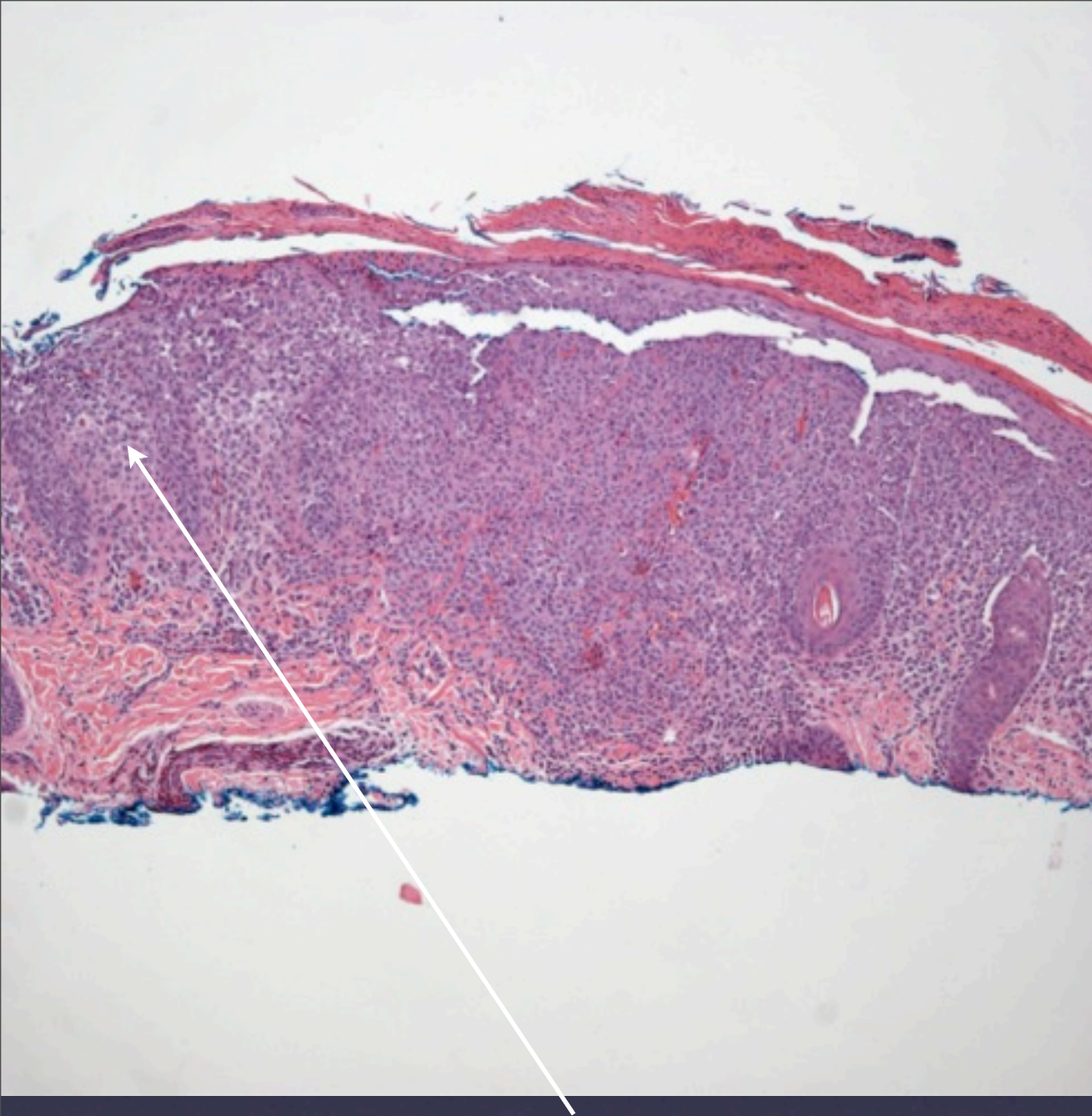


CD 1a

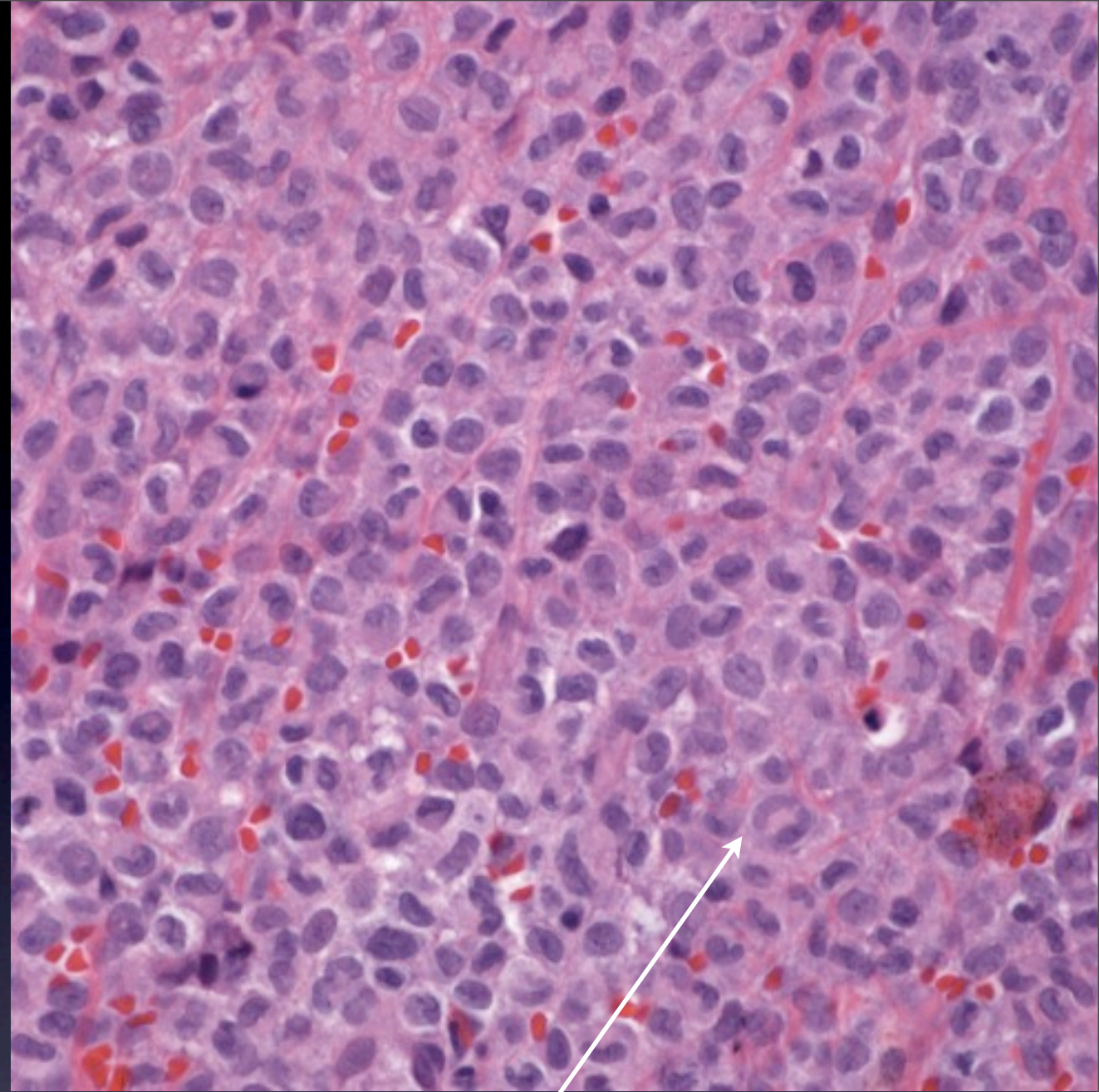
S-100



Langerhans Cell Histiocytosis

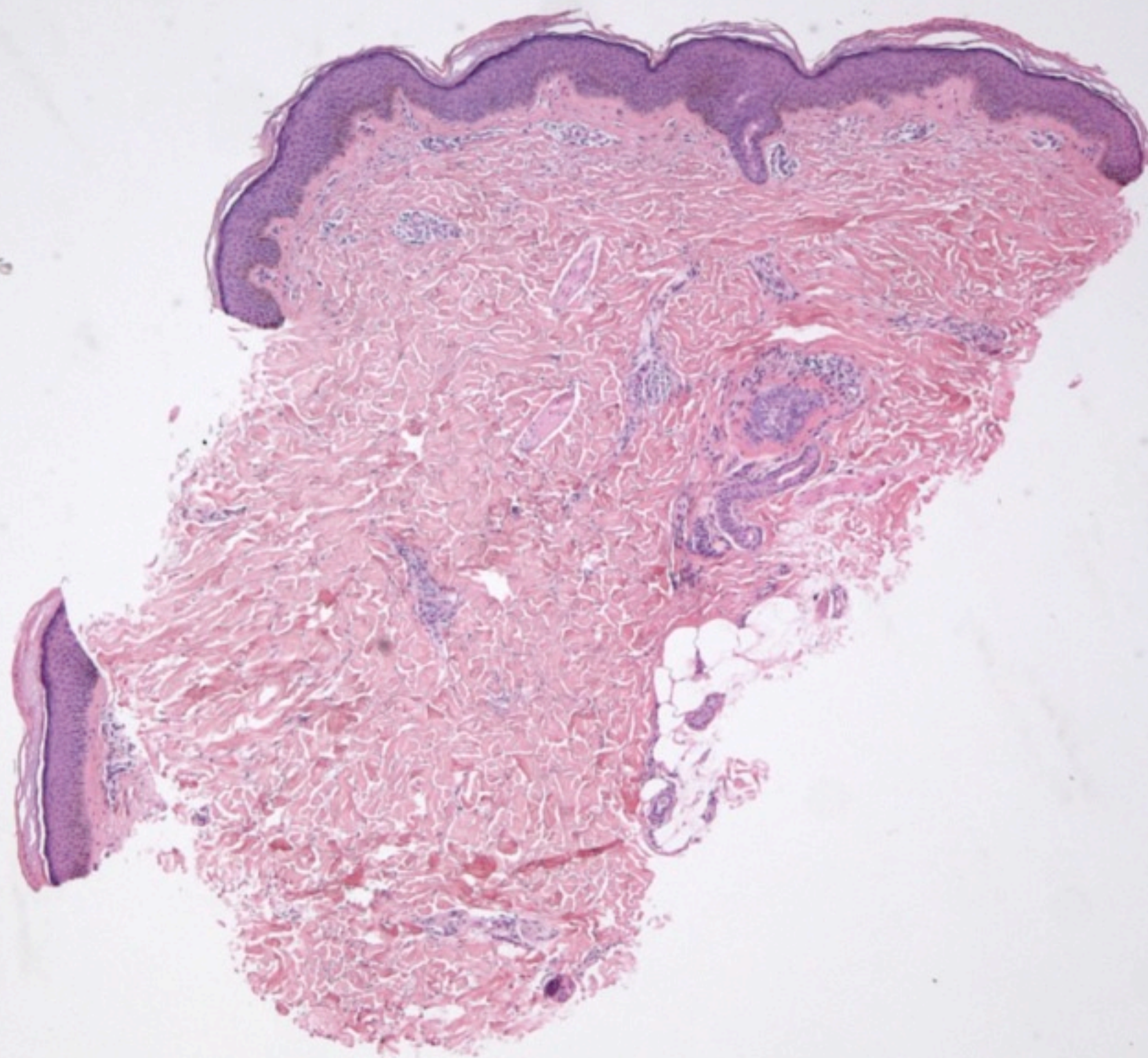


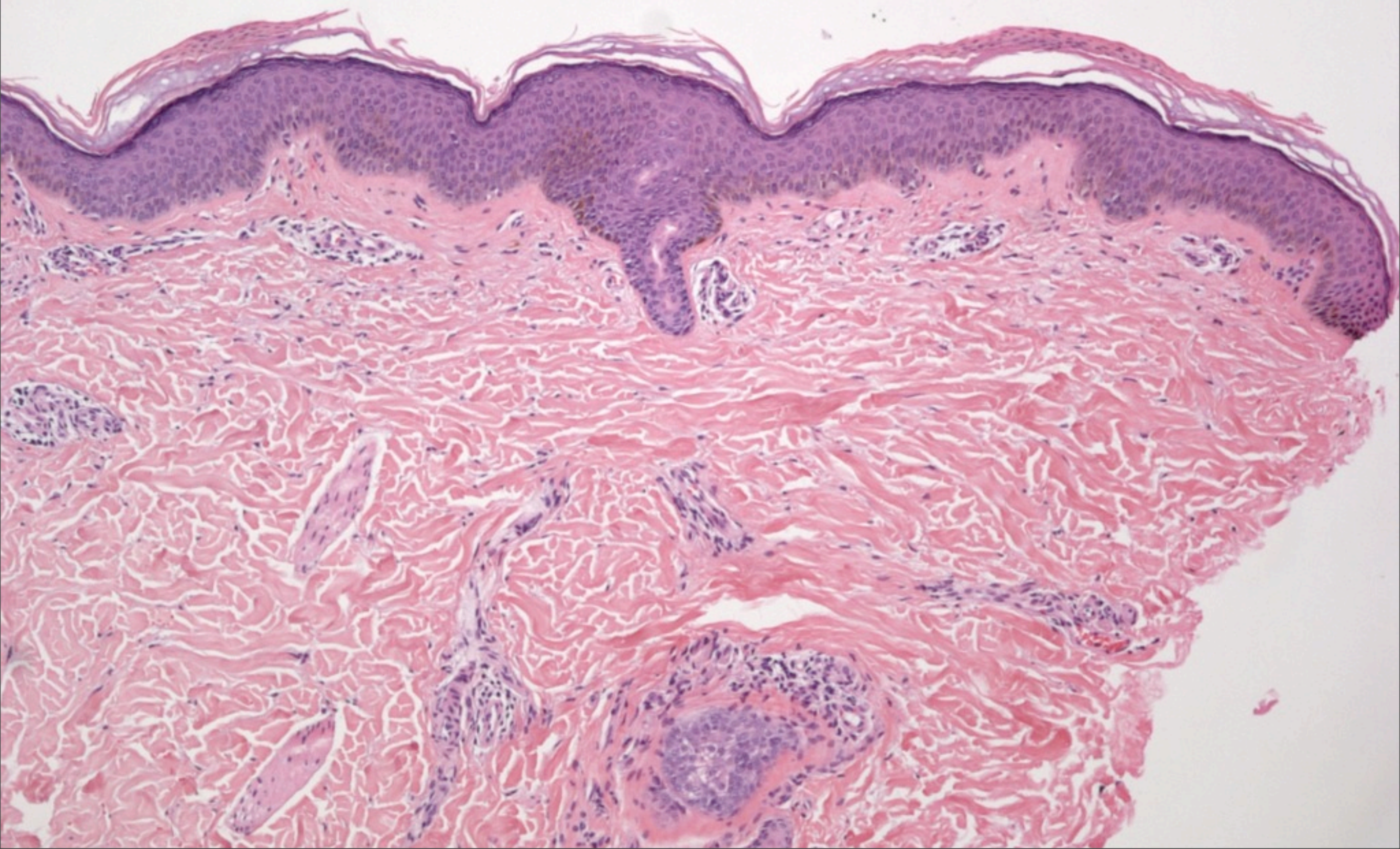
Effacement of DE Junction
by Langerhans Cells

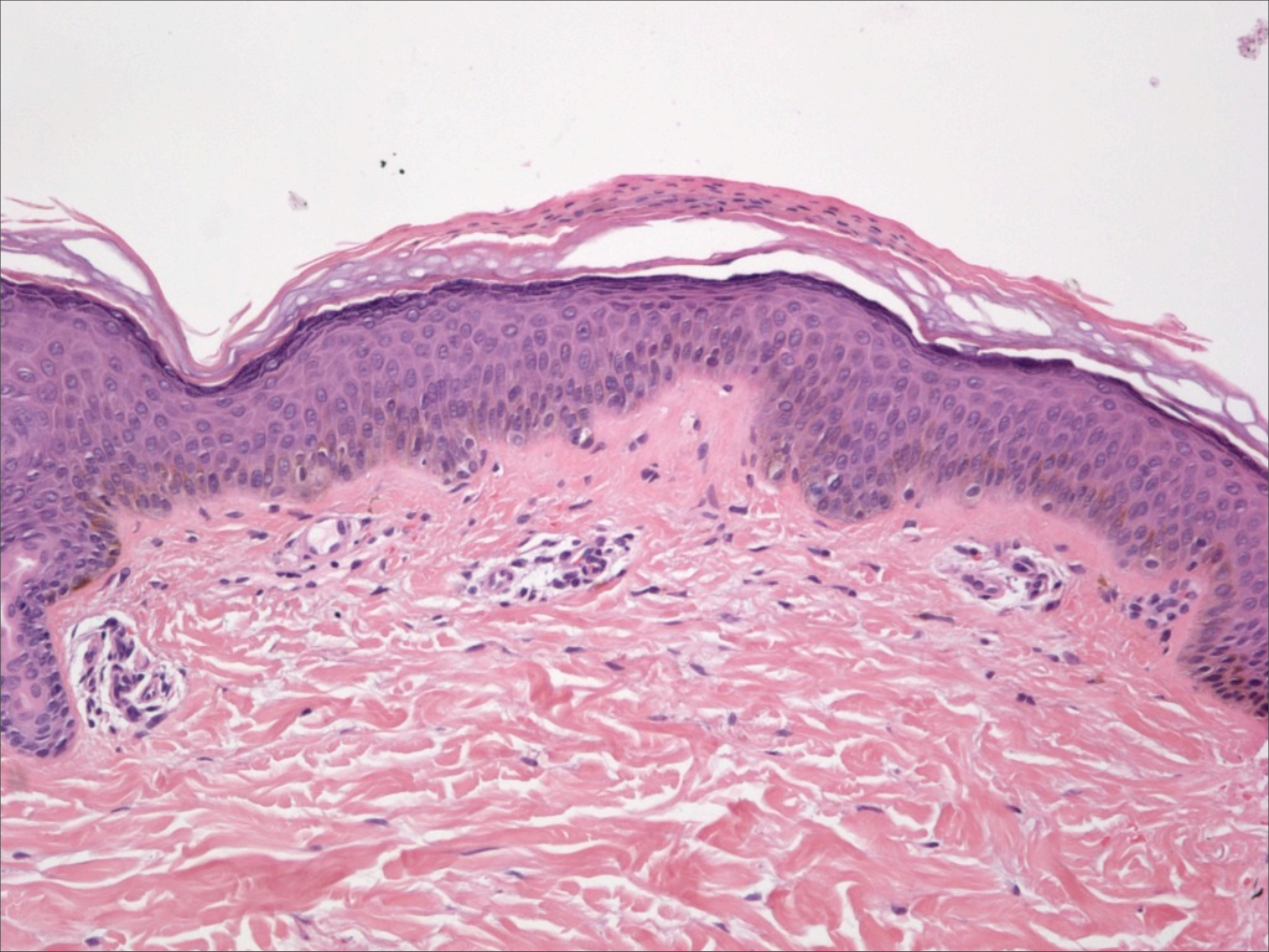


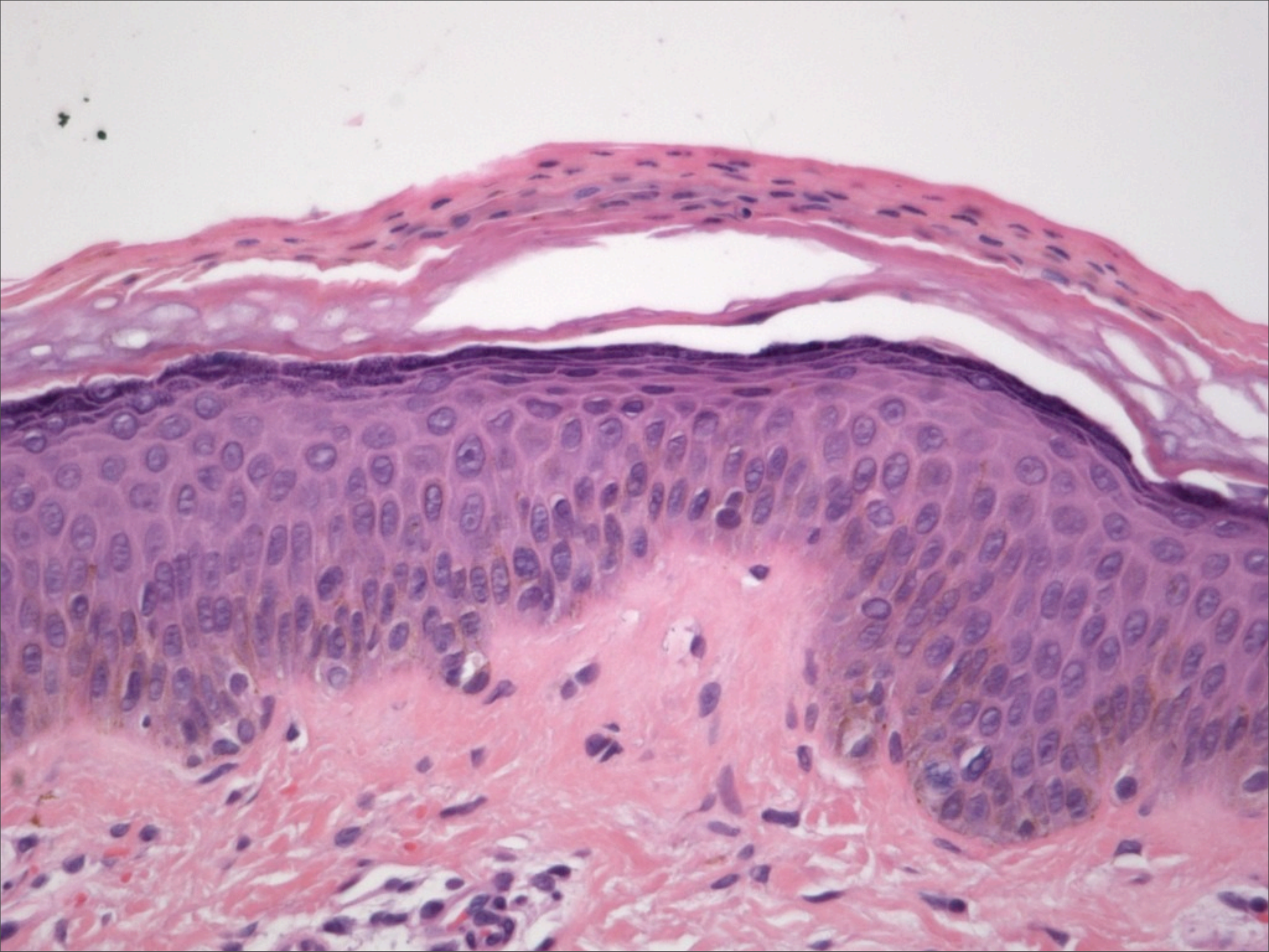
Reniform cells admixed
with eosinophils

Confirm with CD1a/S100



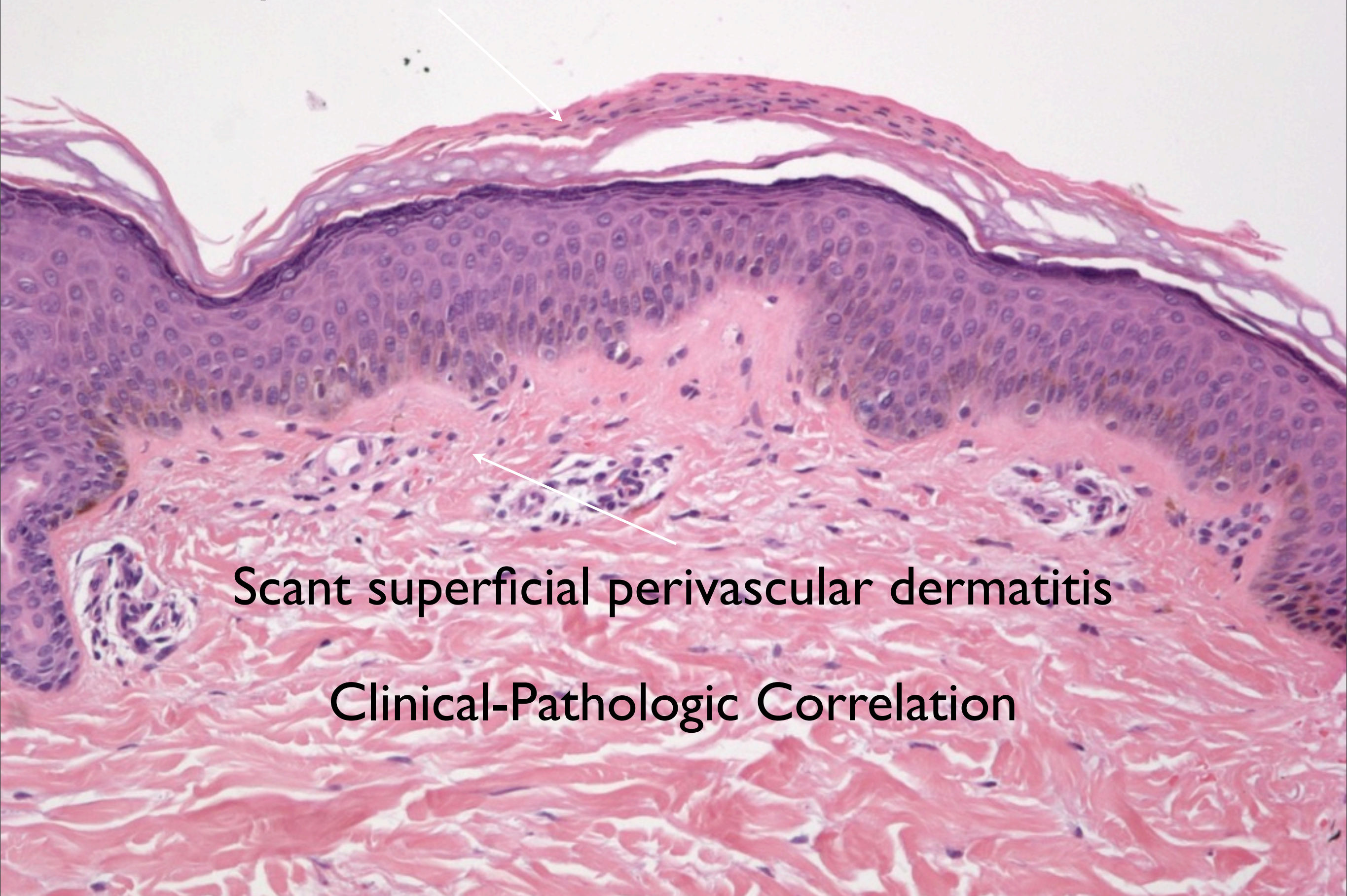






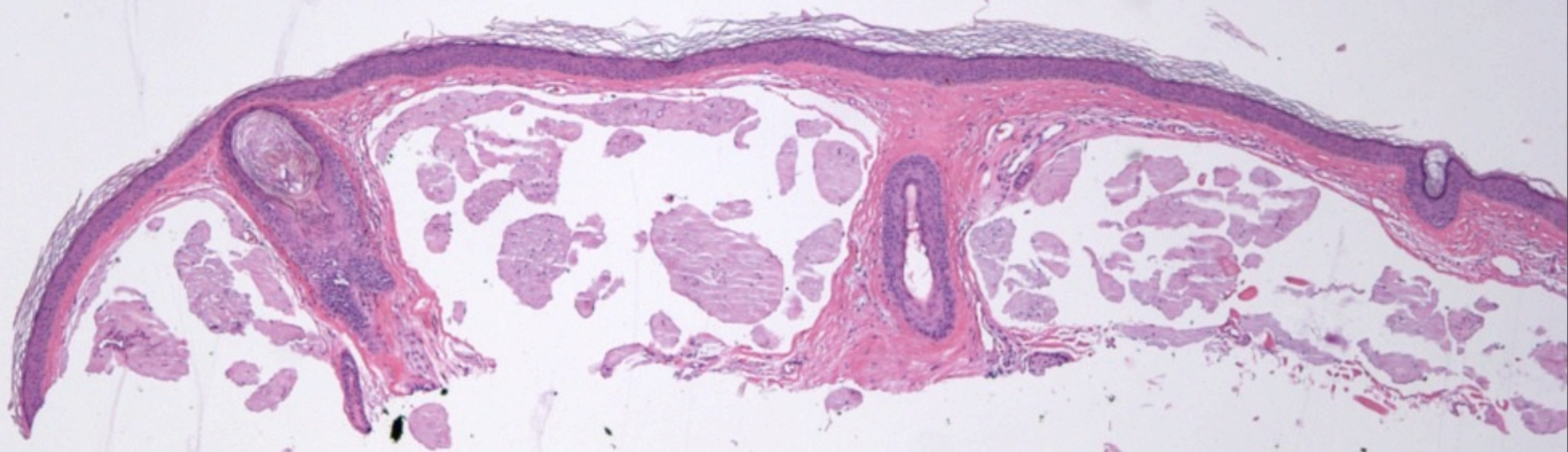
Pityriasis alba

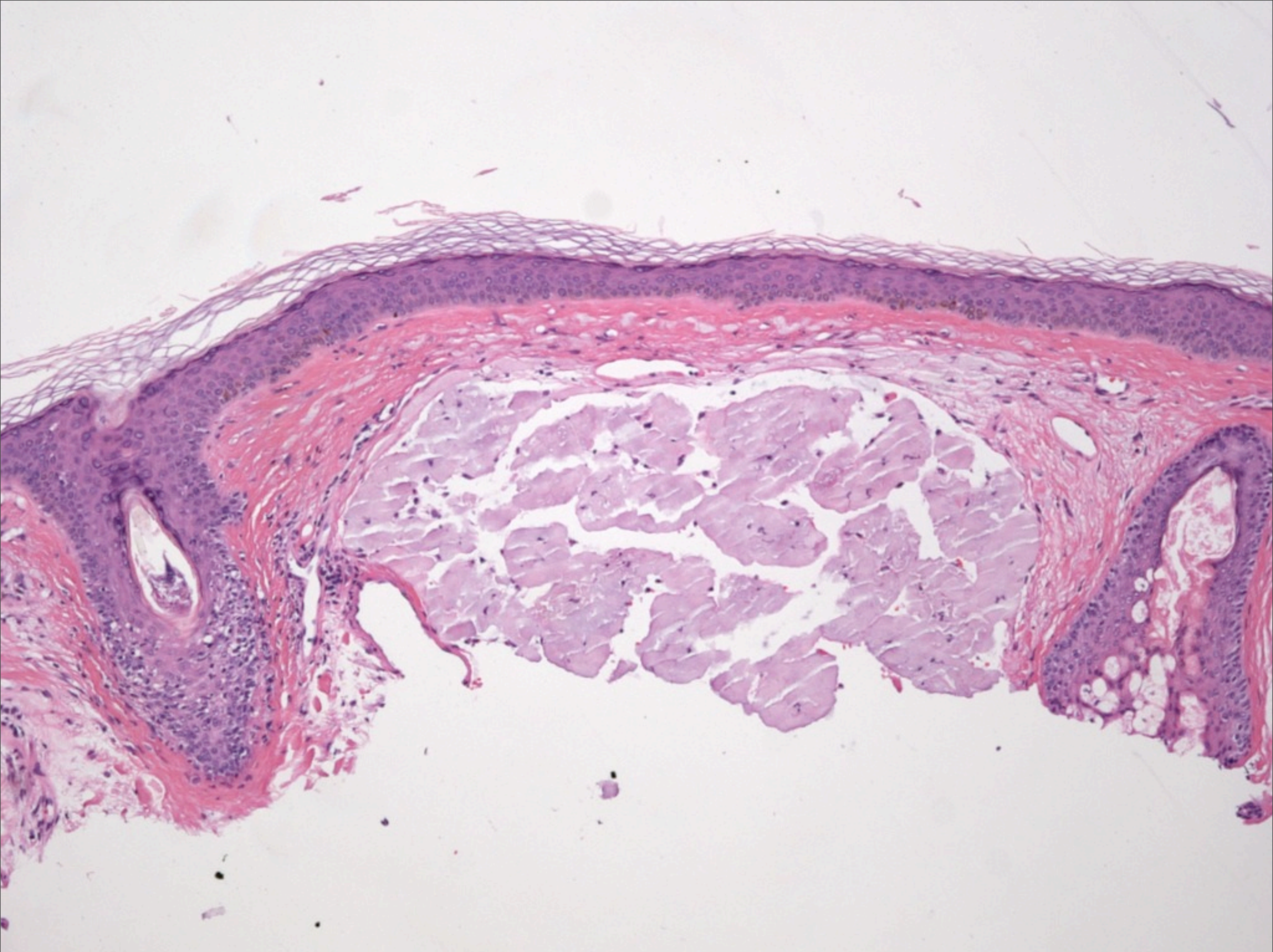
Fine parakeratotic scale

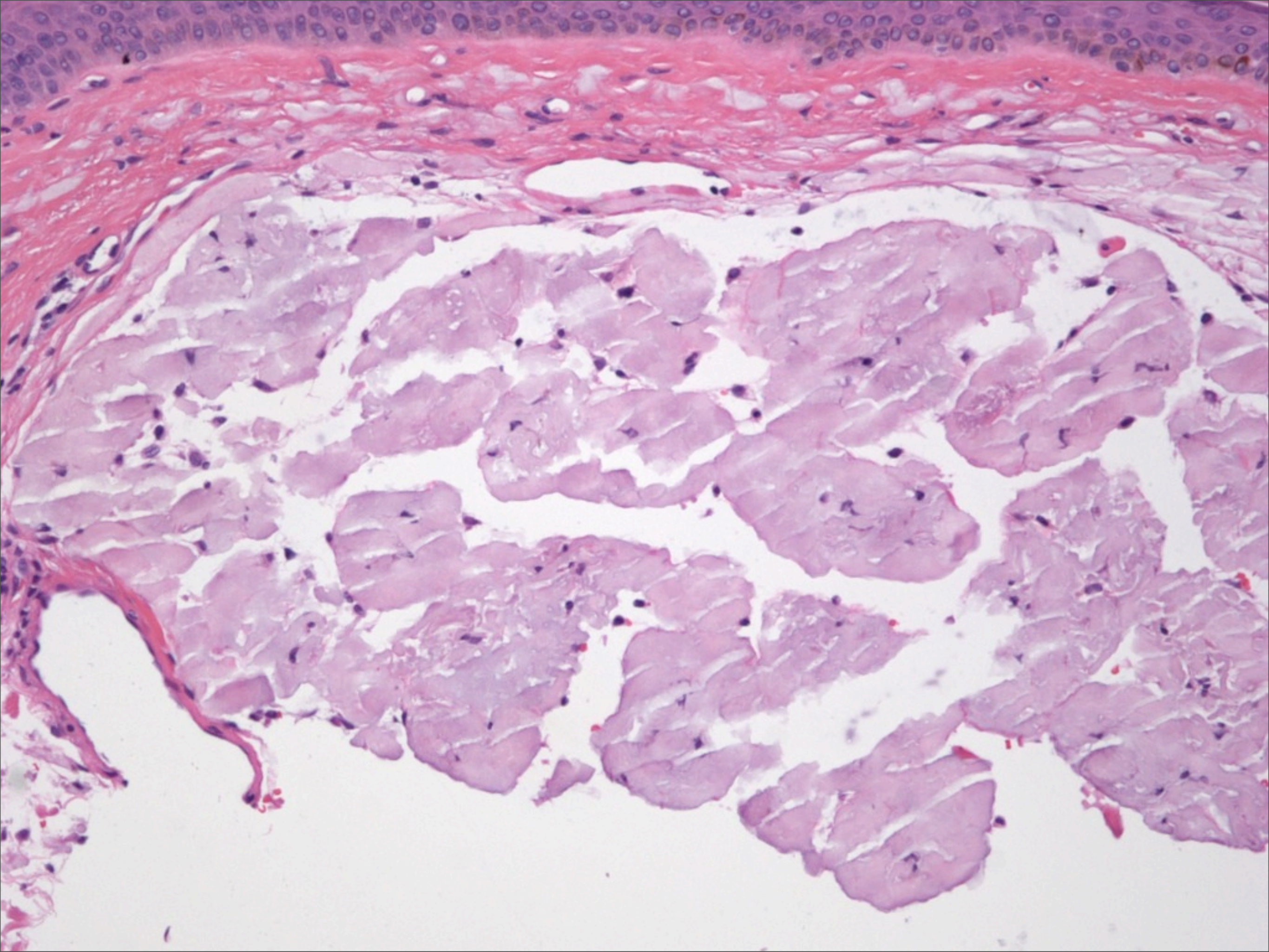


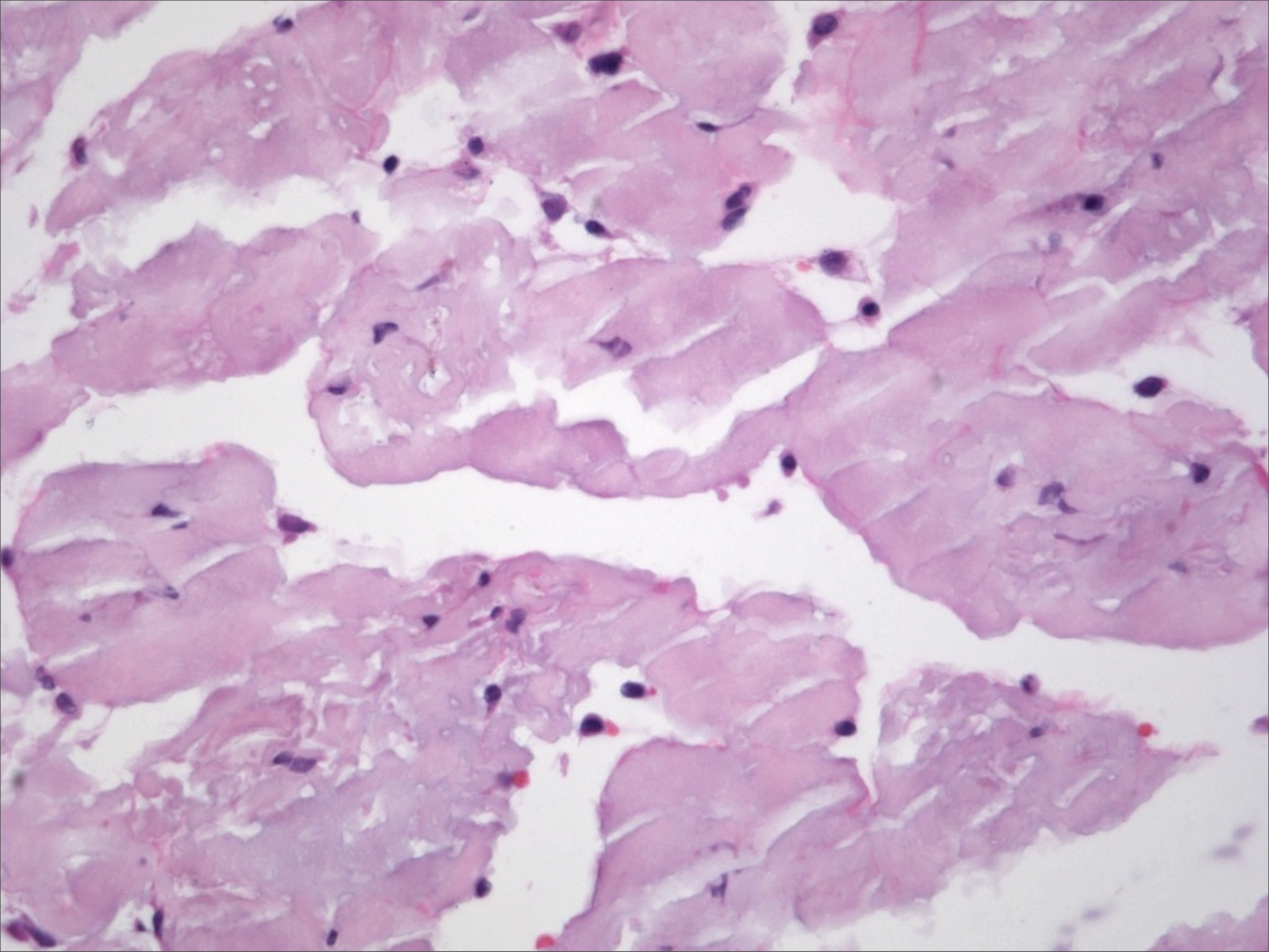
Scant superficial perivascular dermatitis

Clinical-Pathologic Correlation

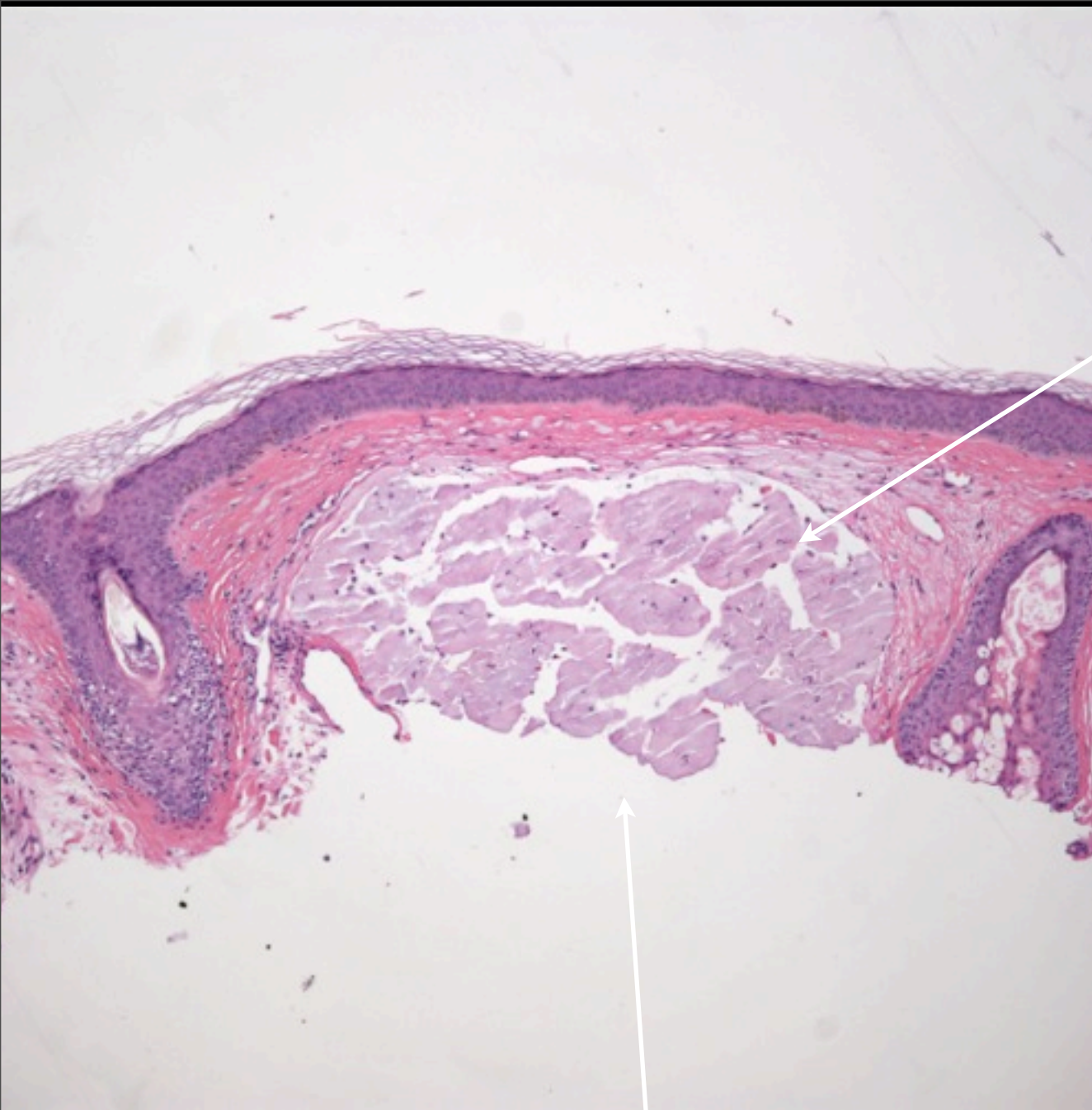








Colloid Miliun

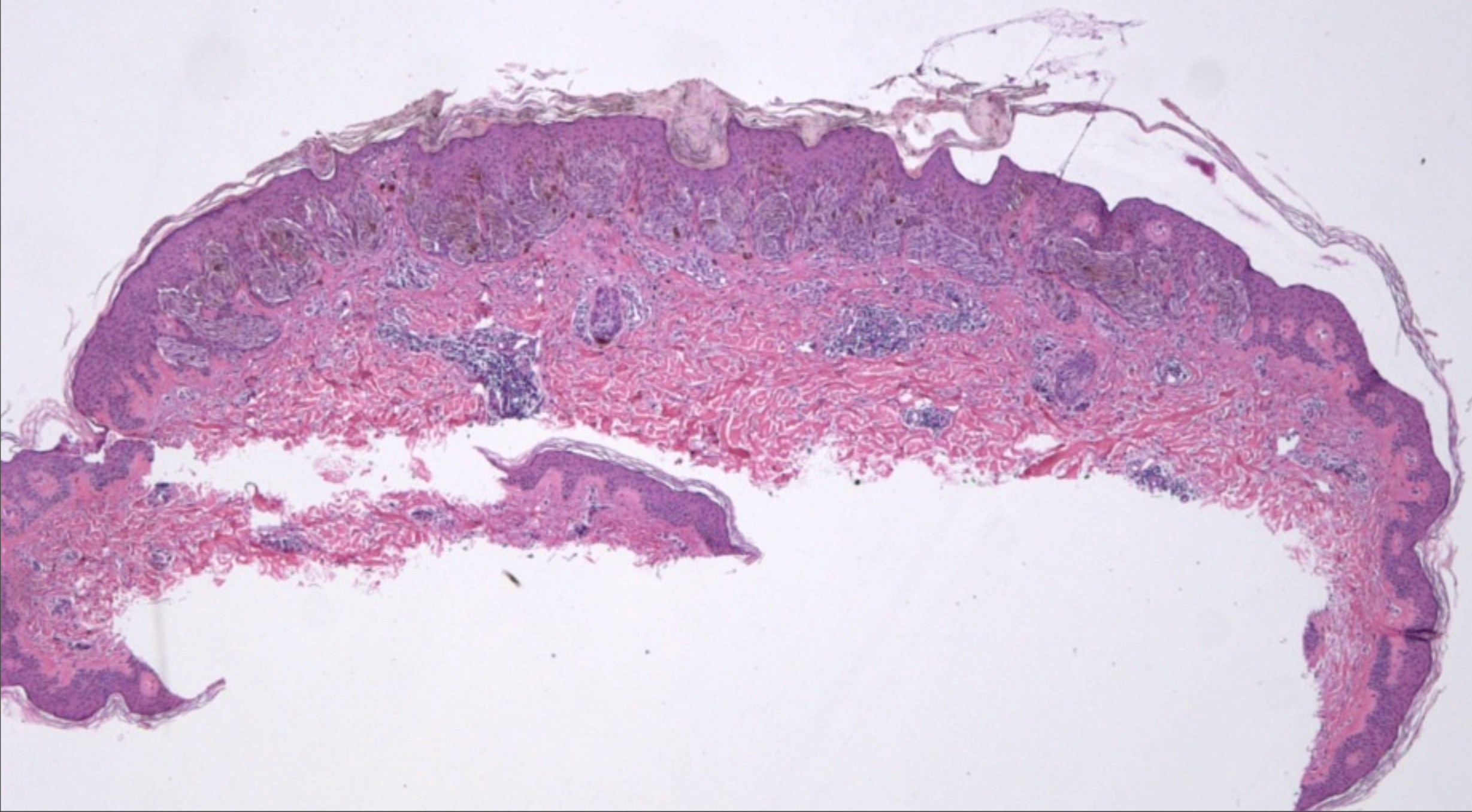


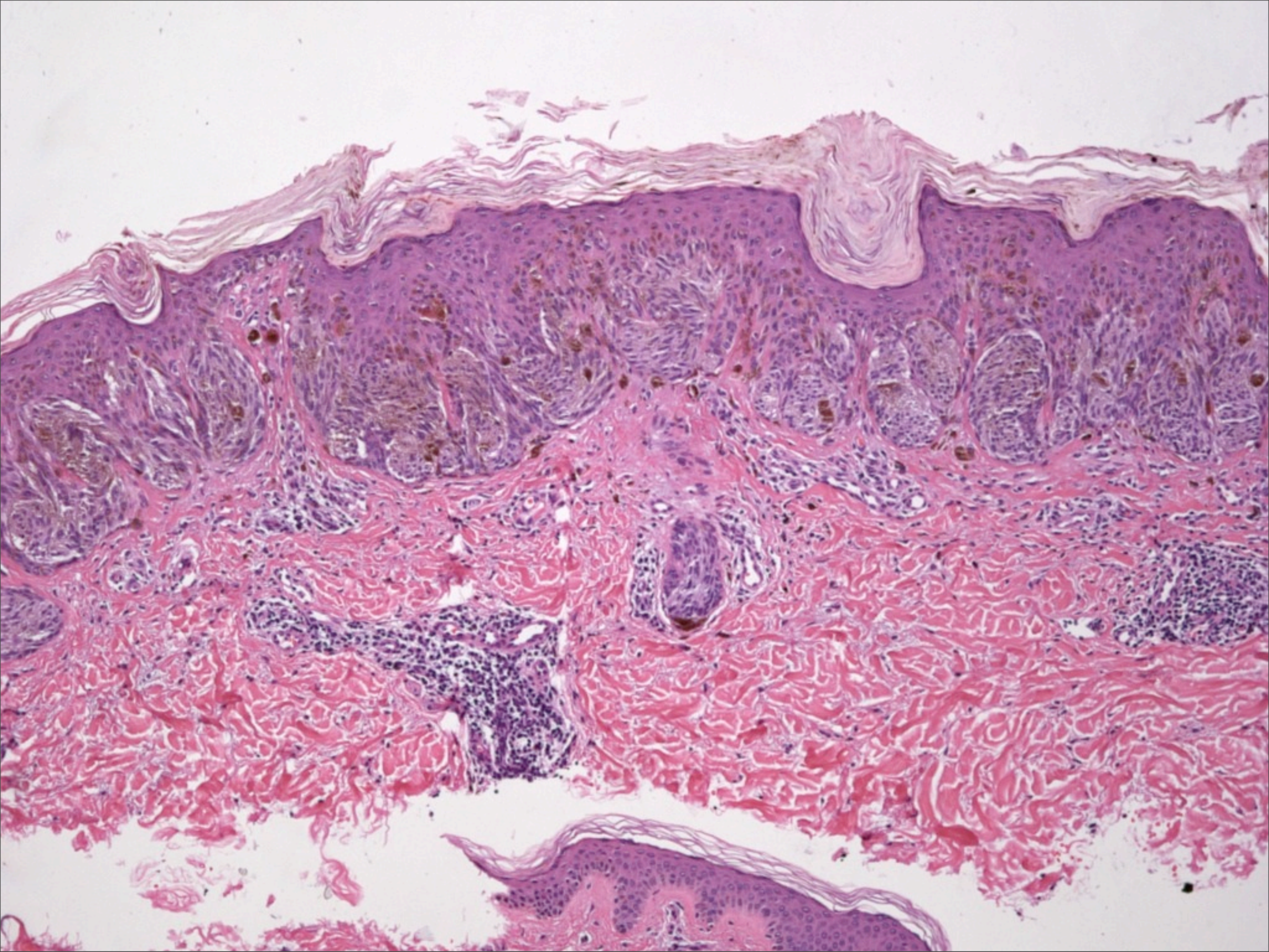
Cracking

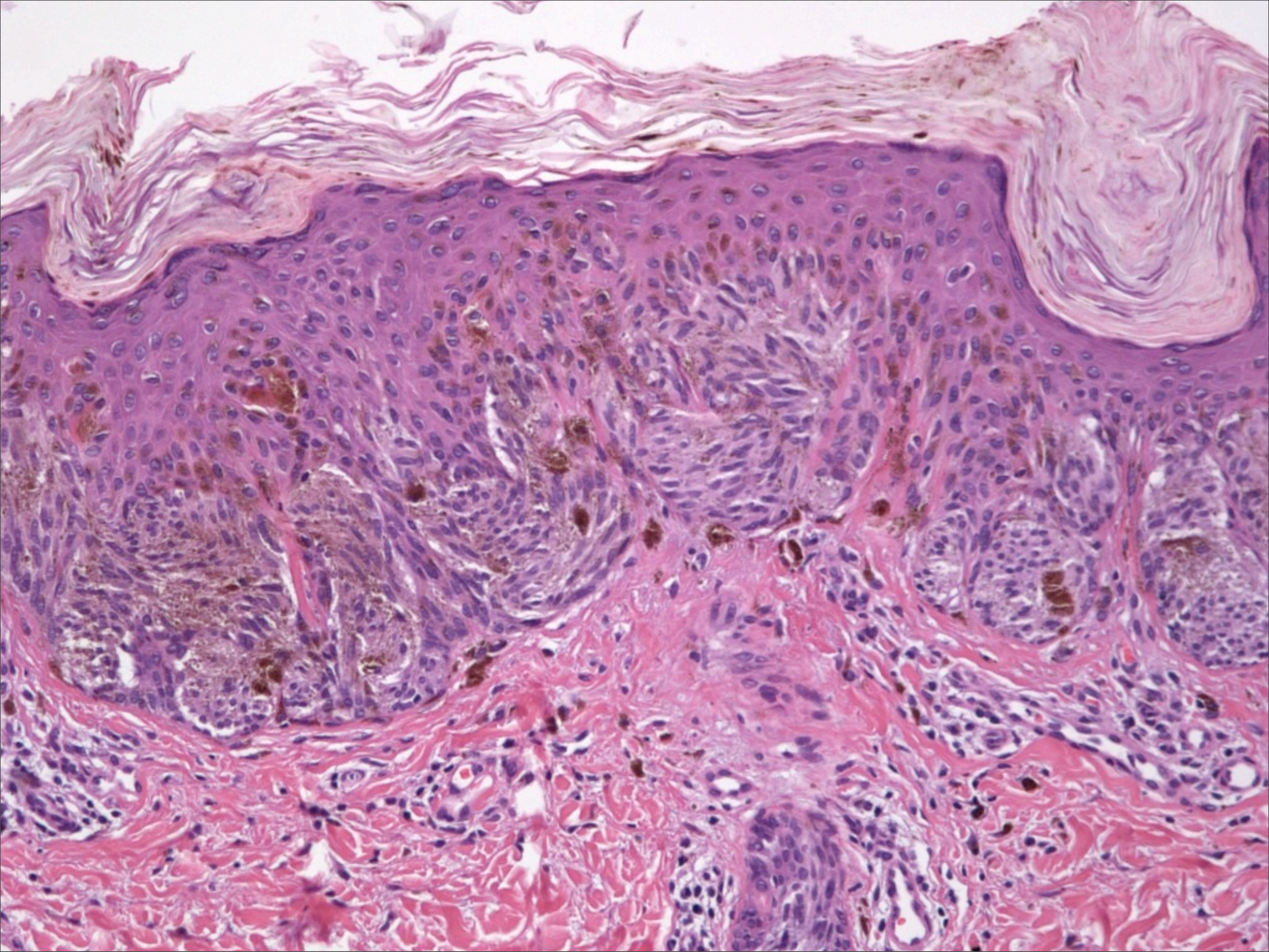
Acellular

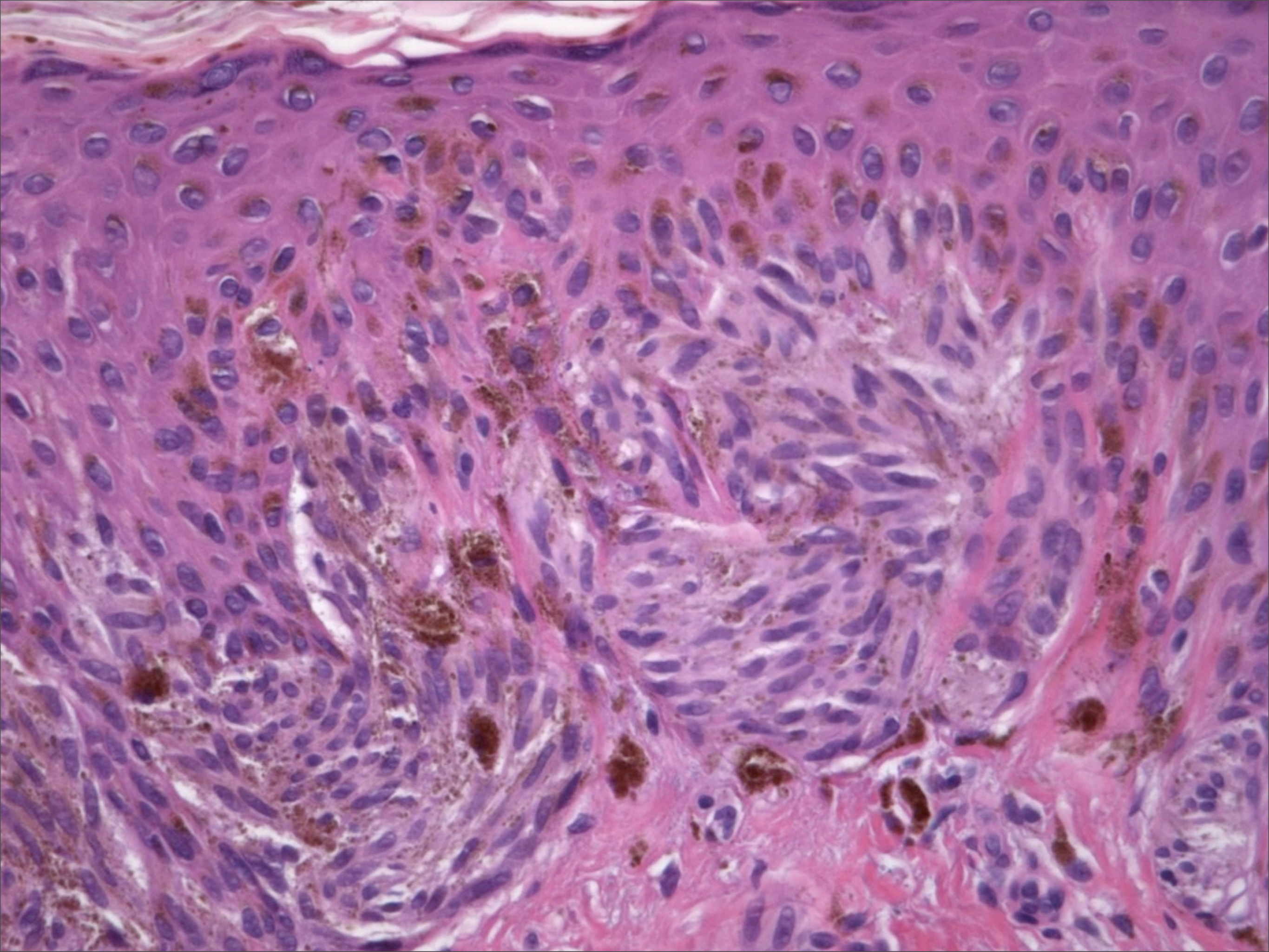
Negative for amyloid stains

Nodular dermal hyaline deposits

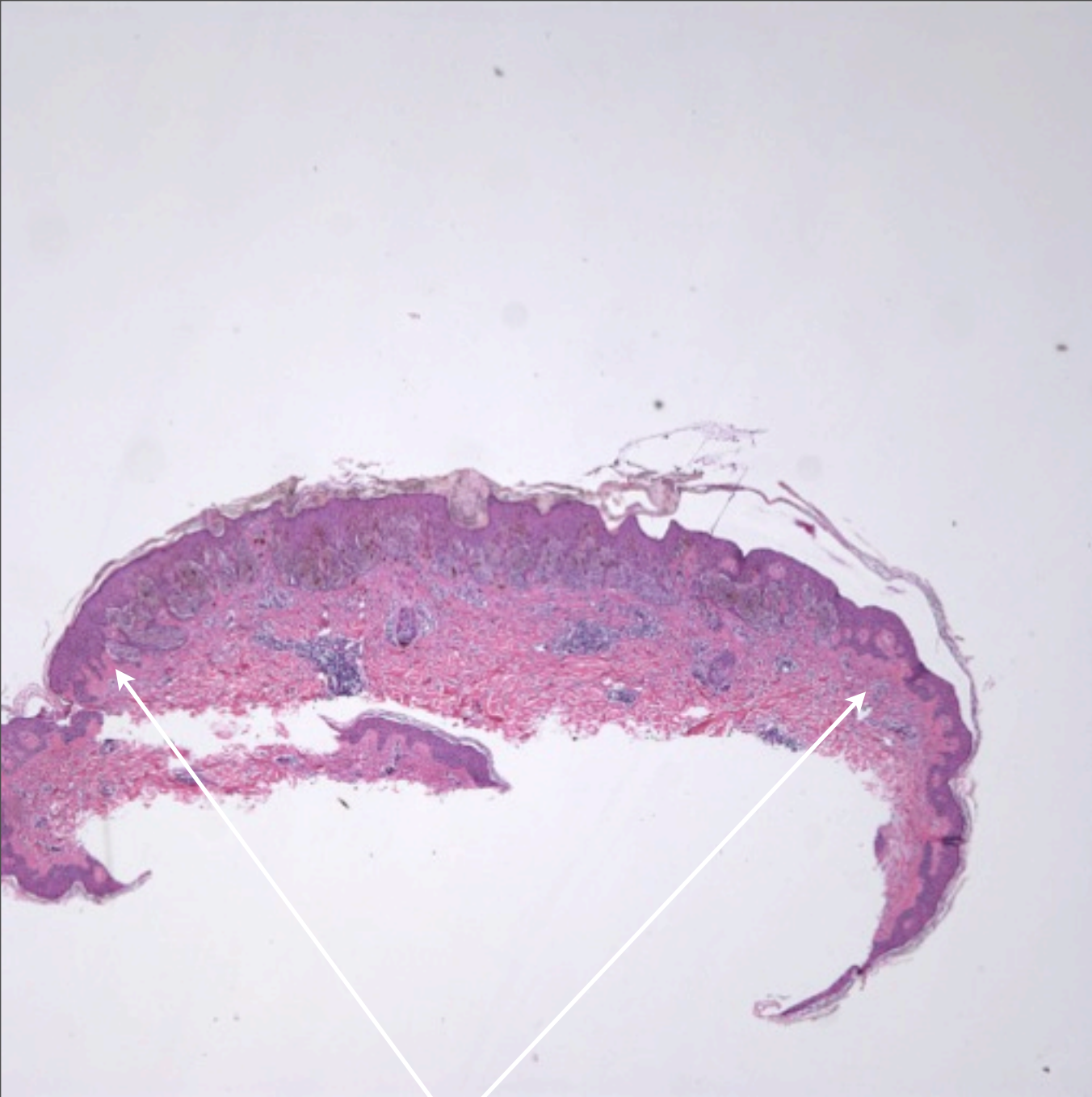








Pigmented Spindle Cell Nevus of Reed



Pigmented spindled
melanocytes

Symmetric and sharply
circumscribed at periphery